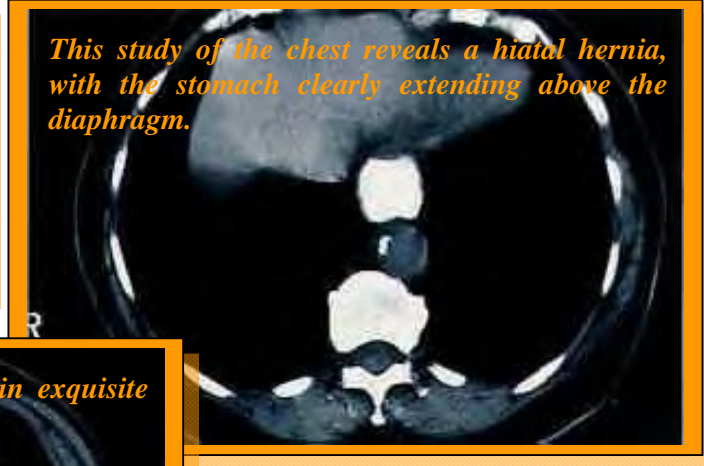


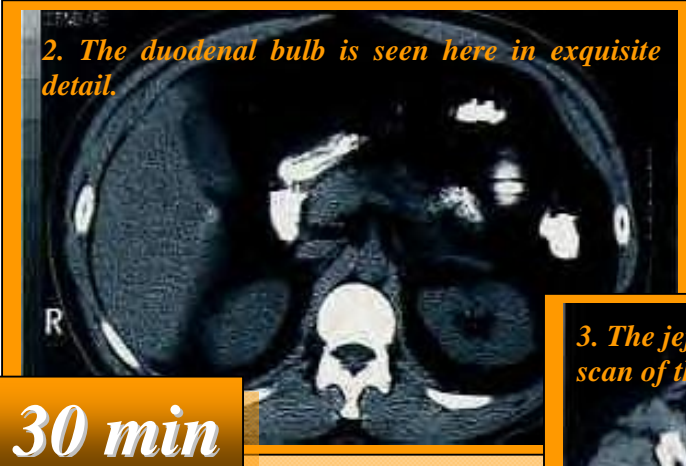CT Views Today



This study of the chest reveals a hiatal hernia, with the stomach clearly extending above the diaphragm.

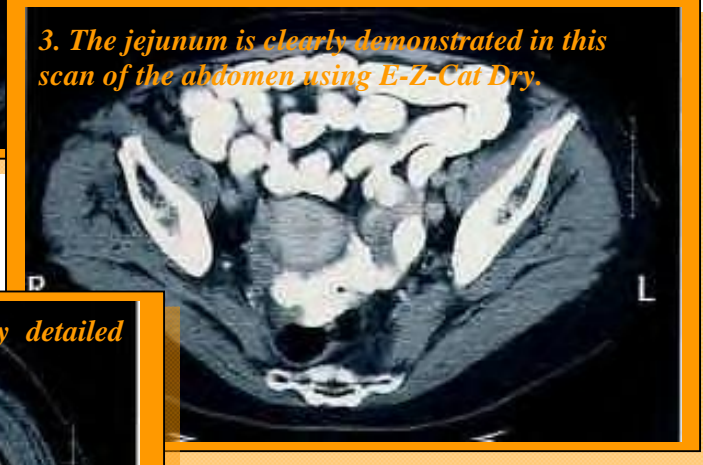

2. The duodenal bulb is seen here in exquisite detail.

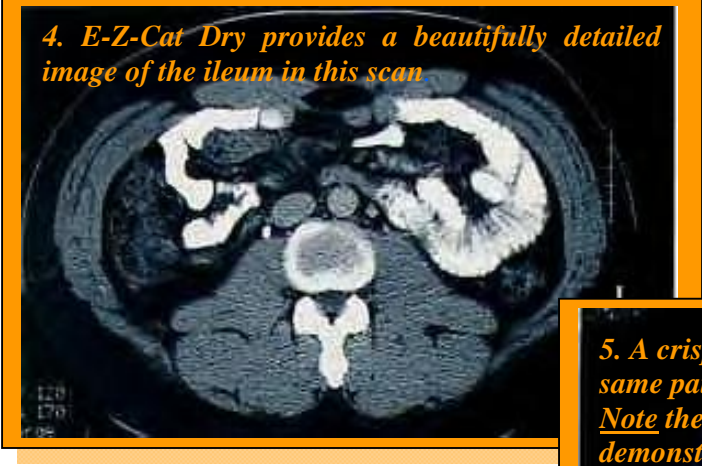

30 min

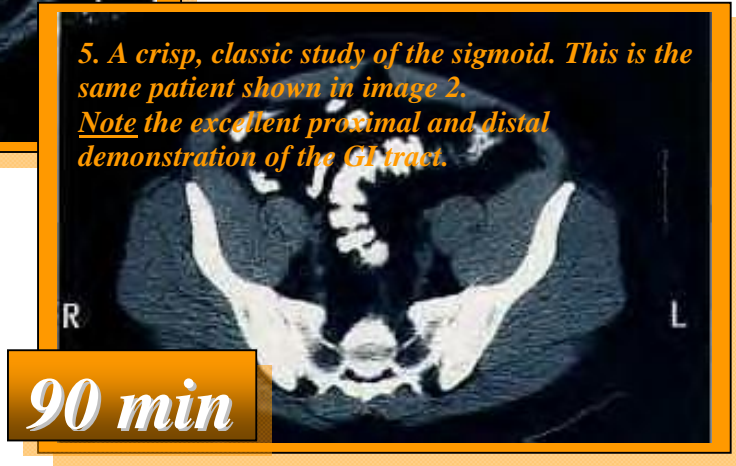
3. The jejunum is clearly demonstrated in this scan of the abdomen using E-Z-Cat Dry.



4. E-Z-Cat Dry provides a beautifully detailed image of the ileum in this scan.



5. A crisp, classic study of the sigmoid. This is the same patient shown in image 2. Note the excellent proximal and distal demonstration of the GI tract.



90 min